

## Portal Vein Thrombosis due to Vaccine-Induced Immune Thrombotic Thrombocytopenia (VITT) after Covid Vaccination with ChAdOx1 nCoV-19

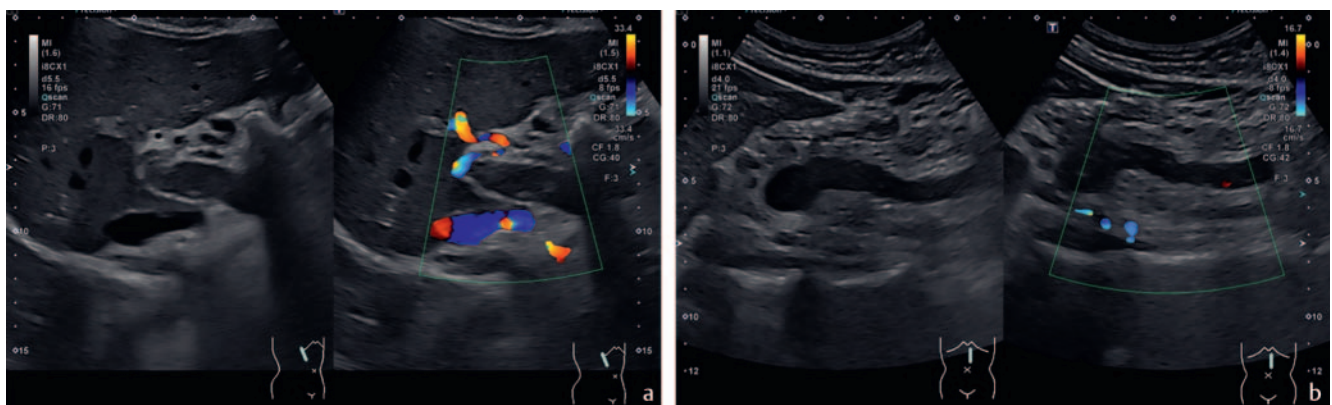
### Pfortaderthrombose bei immunthrombotischer Thrombozytopenie (VITT) nach Impfung gegen SARS-CoV-2 mit Adenovirus-basiertem Vakzin (ChAdOx1 nCoV-19)

A 29-year-old male graduate student was vaccinated with the recombinant adenoviral vector encoding the spike protein antigen of SARS-CoV-2 (Astra-Zeneca Vaxzevria). He developed upper abdominal pain without nausea or vomiting 14 days after vaccination. The abdominal symptoms were followed by headache two days later. He interpreted his symptoms as stress related to the finalization of his master's degree thesis. Two days later he noticed skin petechia and went to the emergency medical service. The clinical presentation with headache and a high D-dimer concentration prompted his referral to the university hospital. At admission, the patient was afebrile and had no signs of infection and no neurologic deficits. Laboratory results were significant for severe thrombocytopenia (21 000/ml). Magnetic resonance imaging (MRI) of his head showed thrombosis of the transversus/sigmoideus transition extending towards the left vena jugularis interna. Abdominal ultrasound revealed thrombosis of the portal vein including the intrahepatic branches and extending to the confluence of the splenic vein and superior mesenteric vein (► Fig. 1). No free fluid and no bowel wall thickening were seen. Spleen size was normal. Vaccine-induced immune thrombotic thrombocytopenia (VITT) was suspected in this

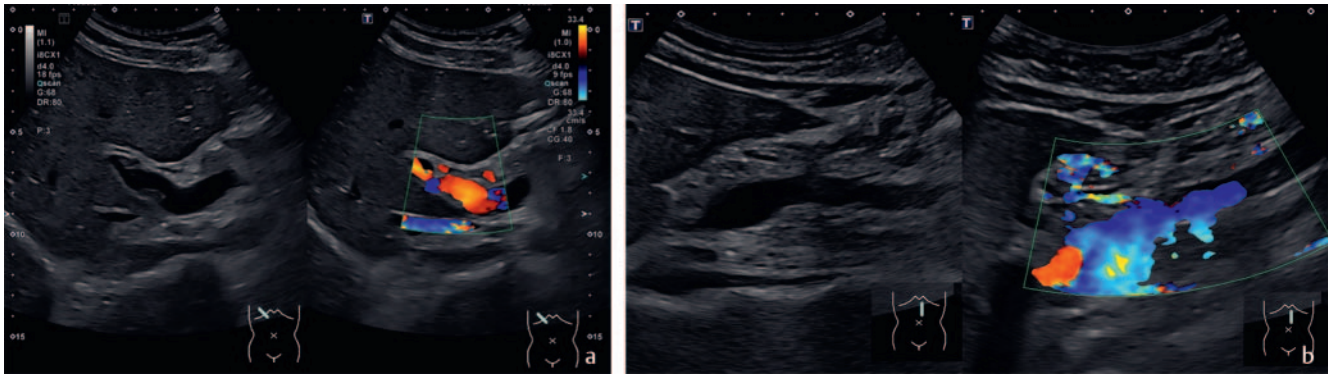
otherwise healthy young man, who had not been exposed to heparin before. Argatroban was administered at a dose of 2 micrograms/kg/min as an intravenous infusion. The patient was treated with intravenous immunoglobulin (1 g per kilogram per day for two days) and prednisolone (100 mg per day for three days). Platelet counts normalized within three days. Oral anticoagulation with apixaban was started when the platelet count was >100 000/ml. The patient's symptoms resolved within 72 hours, follow-up abdominal ultrasound four days after admission showed subtotal resolution of thrombosis indicating a favorable outcome (► Fig. 2). The patient was discharged from hospital six days after admission. Antibody-mediated PF4-dependent platelet activation was later confirmed in a blood sample taken before intravenous immunoglobulin treatment.

In March 2021, vaccine-induced immune thrombotic thrombocytopenia (VITT) was first described in patients after vaccination with the recombinant adenoviral vector encoding the spike protein antigen of the severe acute respiratory syndrome coronavirus [1, 2]. Of 16 published patients (11 in Germany and Austria, 5 in Norway) with unusual thrombotic events, 9 died of VITT [1, 2]. The predominant location of thrombosis was the cerebral sinus veins. Addi-

tional splanchnic vein thrombosis was reported in 3/16 patients. An additional case report with cerebral sinus venous and portal vein thrombosis, similar to our case, showed that immediate high-dose intravenous immunoglobulins followed by direct thrombin-inhibitor treatment is crucial for survival in Sars-CoV2-adenoviral vector vaccine-induced immune thrombotic thrombocytopenia (VITT) [3]. VITT is a new phenomenon. Clinicians should be aware that in some patients, thrombosis can develop at unusual sites such as the brain or abdomen. Interestingly, in our patient, abdominal pain was the first symptom preceding headache. If abdominal symptoms are accompanied by thrombocytopenia, it can represent an adverse effect of prior COVID-19 vaccination. Abdominal ultrasound should include careful exploration of the splanchnic vessels. With clinical awareness and an early diagnosis via ultrasound, acute portal vein thrombosis usually has a good prognosis when treated before the occurrence of intestinal infarction [4]. Thrombosis associated with a reduction in platelet count, sometimes accompanied by bleeding, has been observed in very rare cases (less than 0.01 %, RKI information sheet May 12,2021) following vaccination with Astra-Zeneca Vaxzevria. The majority of these cases occurred within three weeks after vaccination and predominantly in



► Fig. 1 Portal vein thrombosis a and mesenteric vein thrombosis b. B-mode US image (left side) and color Doppler image (right side).



► **Fig. 2** Recanalization of the portal vein **a** and mesenteric vein **b**. B-mode US image (left side) and color Doppler image (right side).

persons below the age of 60. Some of the cases described ended fatally or with permanent damage [5].

### Conflict of Interest

The authors declare that they have no conflict of interest.

### Acknowledgement

We thank the patient for his agreement to share his medical case with the scientific community.

### Authors

Deike Strobel, Sophie Haberkamp, Sebastian Zundler

Internal medicine I, University of Erlangen, Germany

### Correspondence

Prof. Deike Strobel

Internal medicine I, University of Erlangen  
Ulmenweg 18  
91058 Erlangen  
Germany  
Tel.: +49/91 31/8 53 50 00  
Fax: +49/91 31/8 53 52 52  
deike.strobel@uk-erlangen.de

### References

- [1] Greinacher A, Thiele T, Warkentin TE et al. Thrombotic thrombocytopenia after ChAdOx1 nCoV-19 vaccination. *N Engl J Med* 2021. doi:10.1056/NEJMoa2104840
- [2] Schultz NH, Sørvoll IH, Michelsen AE et al. Thrombosis and thrombocytopenia after ChAdOx1 nCoV-19 vaccination. *N Engl J Med* 2021. doi:10.1056/NEJMoa2104882
- [3] Graf T, Thiele T, Klingebiel R et al. Immediate high-dose intravenous immunoglobulins followed by direct thrombin-inhibitor treatment is crucial for survival in Sars-COVID-19-adenoviral vector vaccine-induced immune thrombotic thrombocytopenia VITT with cerebral sinus venous and portal vein thrombosis. *J Neurol* 2021; 22: 1–3
- [4] Chawla YK, Bodh V. Portal Vein Thrombosis. *J Clin Exp Hepatol* 2015; 5: 22–40
- [5] <https://www.rki.de/DE/Content/Infekt/Impfen/Materialien/Downloads-COVID-19-Vektorimpfstoff/Aufklaerungsbogen-Englisch>

### Bibliography

Ultraschall in Med 2021; 42: 551–552

Published online: 2021

DOI 10.1055/a-1579-9303

ISSN 0172-4614

© 2021. Thieme. All rights reserved.

Georg Thieme Verlag KG, Rüdigerstraße 14, 70469 Stuttgart, Germany